

胃转流术后远端肠黏膜形态及生长因子表达的变化

毛天巍¹ 陈郁希² 李 强^{3△} 李学超¹ 阚 毅¹

(1 大邑县中医医院普通外科 2 大邑县第二人民医院 成都 四川 611330 3 成都军区总医院心内科 成都 四川 610083)

摘要 目的 探讨胃转流术后远端肠管黏膜的适应性变化及生长因子的表达情况。方法 将 8 周龄的 Wistar 大鼠随机分为对照组、假手术组和胃转流术组 术后 8 周取吻合口远端肠管行常规病理切片检查 测量肠黏膜厚度和绒毛高度 采用免疫荧光法检测肠黏膜中表皮生长因子(EGF)和胰岛素样生长因子-1(IGF-1)的表达。结果 胃转流术组黏膜厚度(672 ± 39 与 $500 \pm 31 \mu\text{m}$ $P < 0.01$)和绒毛高度(445 ± 19 与 $342 \pm 15 \mu\text{m}$ $P < 0.01$)均显著高于假手术组($P < 0.01$) 而对照组和假手术组间均无显著差异。与假手术组比较 胃转流术组肠黏膜中 EGF 和 IGF-1 的表达显著升高($P < 0.01$) 而对照组和假手术组间无显著差异。结论 胃转流术后远端肠管黏膜发生适应性增生 同时伴随着 EGF 和 IGF-1 表达水平的升高。

关键词 胃转流术 表皮生长因子 胰岛素样生长因子-1 肠粘膜

中图分类号 R656.7 文献标识码 A 文章编号 1673-6273(2011)18-3446-03

Changes in Morphology of Intestinal Mucosa and Expressions of Growth Factors after Gastric Bypass Surgery in Rats

MAO Tian-wei¹, CHEN Yu-xi², LI Qiang^{3△}, LI Xue-cai¹, HAN Yi¹

(1 Department of General Surgery, Dayi Chinese Medicine Hospital; 2 the 2nd People's Hospital of Dayi, Chengdu 611330;

3 Department of Cardiology, General Hospital of Chengdu Military Area Command, Chengdu 61008, China)

ABSTRACT Objective: To investigate the changes in the morphology of intestinal mucosa and the expressions of growth factors after gastric bypass surgery (GBP). **Methods:** Wistar rats (eight-week old) were divided into three groups: control group, sham group, and GBP group. The distal bowel was collected after 8 weeks following the surgery. The mucosal thickness and villus height were measured by histological analysis. The expressions of epidermal growth factor (EGF) and insulin-like growth factor 1 (IGF-1) were detected by immunofluorescence. **Results:** The mucosal thickness (672 ± 39 vs. $500 \pm 31 \mu\text{m}$, $P < 0.01$) and villus height (445 ± 19 vs. $342 \pm 15 \mu\text{m}$, $P < 0.01$) in GBP group were significantly higher than sham group. In addition, the mucosal thickness and villus height were similar between control group and sham group. Compared with sham group, the expressions of EGF and IGF-1 were significantly increased (both $P < 0.01$). Additionally, the expressions of EGF and IGF-1 were similar between control group and sham group. **Conclusion:** Interstitial mucosal adaptation occurred in distal bowel, which is associated with increased expressions of EGF and IGF-1.

Key words: Gastric bypass surgery; Epidermal growth factor; Insulin-like growth factor 1; Mucosa

Chinese Library Classification: R656.7 **Document code:** A

Article ID: 1673-6273(2011)18-3446-03

前言

胃转流术(gastric bypass surgery, GBP)已被用于重度肥胖和 2 型糖尿病的治疗^[1-5]。GBP 通过旷置十二指肠和近端空肠而发挥减肥和降糖作用^[6-9]。既往的研究多集中关注 GBP 对糖脂代谢和胃肠激素变化的影响,对吻合口远端肠管黏膜形态及功能的关注较少。在短肠综合征模型中,残余肠段黏膜会发生非常显著的代偿性改变,表现为肠粘膜和腺体的增生,这可能部分代偿了切除肠段的功能^[10,11]。GBP 旷置了整段十二指肠和近段空肠,而吻合口远端肠管是否发生适应性表达尚不明确。本研究拟构建 GBP 大鼠动物模型,检测肠黏膜高度和绒毛厚度,并检测肠黏膜中表皮生长因子(epidermal growth factor, EGF)和胰岛素样生长因子-1 (insulin-like growth factor 1, IGF-1) 的表

达。

1 材料与方法

1.1 实验动物和试剂

健康雄性 Wistar 大鼠 (8 周龄)20 只购自四川大学实验动物中心。抗 EGF 抗体和抗 IGF-1 抗体购自北京中杉金桥生物技术有限公司。

1.2 实验方法和步骤

1.2.1 模型建立 大鼠术前禁食 12h,以 10%水合氯醛(2mL/kg)腹腔注射麻醉。胃转流术组大鼠采取保留胃容积的胃转流术(Roux-Y 术),即于胃窦下端离断十二指肠,关闭十二指肠残端,在 Treitz 韧带远端 5cm 切断空肠,远端肠管行胃空肠吻合,距吻合口 4cm 处空肠与近端肠管作端侧吻合,旷置十二指肠和近段空肠,术中保留胃的原始容积。假手术组大鼠在离断胃窦与十二指肠连接处后再原位吻合,保证两组大鼠手术时间相同。

1.2.2 肠管取材 术后 8 周,大鼠麻醉后取材,去除距吻合口

作者简介 毛天巍 男 学士 主治医师 研究方向:胃肠外科。

E-mail: dr_mtk@yahoo.cn

△通讯作者 李强 电话 028-86570341 E-mail:dr_lq@yahoo.cn

(收稿日期 2011-03-10 接受日期 2011-03-31)

1cm 的肠段 ,从离断处截取长约 2cm 的肠段 ,冰盐水洗净肠内容物 ,用 4%多聚甲醛固定 ,另取 2cm 的肠段 ,用冰盐水洗净肠内容物后迅速置于液氮中速冻后转入 -70℃ 低温冰箱保存备用。

1.2.3 病理检查 多聚甲醛固定后的肠管行石蜡包埋 ,常规切片后脱蜡至水 ,行常规 HE 染色 ,封片后在光学显微镜的 40 倍物镜下观察肠黏膜形态 ,每只大鼠切片 5 张 ,每张切片取 3 个视野进行照相 ,采用计算机软件计算黏膜高度、绒毛厚度和隐窝深度。

1.2.4 免疫荧光 取各组肠管包埋后行冰冻切片 ,在空气中干燥 ,在 -20℃ 冰冻的丙酮中浸泡 5 分钟 ,在 5%胎牛血清中封闭 5 分钟。加用 1:200 的抗 EGF 抗体或抗 IGF-1 抗体孵育 60 分钟 ,再用 PBS 冲洗 3 次 ,室温下加 1:100 的 FITC 或罗丹明标记的 II 抗 30 分钟 ,用 PBS 冲洗后加入 DAPI 染色液室温作用 15 分钟 ,用 PBS 在漂洗后在荧光显微镜下观察 ,选取对应滤光片在 400 倍荧光显微镜下观察并摄相 ,用计算机软件计算荧光强度。

度。

1.3 统计学分析

计量资料以均数± 标准差($\bar{X} \pm S$)表示表示 ,采用 SPSS 软件(11.5 版本)进行统计学分析 ,两组间差异比较采用 t 检验 ,将 $P < 0.05$ 视为有显著性差异。

2 结果

2.1 肠黏膜形态学变化

常规组织切片和 HE 染色显示对照组大鼠的肠黏膜形态基本完整 ,上皮细胞绒毛排列整齐 ;假手术组黏膜厚度(500 ± 31 与 $492 \pm 41 \mu\text{m}$, $P > 0.05$) 和绒毛高度 (342 ± 15 与 $339 \pm 14 \mu\text{m}$, $P > 0.05$)与对照组均无明显差异 ;与假手术组比较 ,胃转流术组黏膜厚度明显增加(672 ± 39 与 $500 \pm 31 \mu\text{m}$, $P < 0.01$) ,绒毛也显著增高(445 ± 19 与 $342 \pm 15 \mu\text{m}$, $P < 0.01$) ,见图 1 表 1。

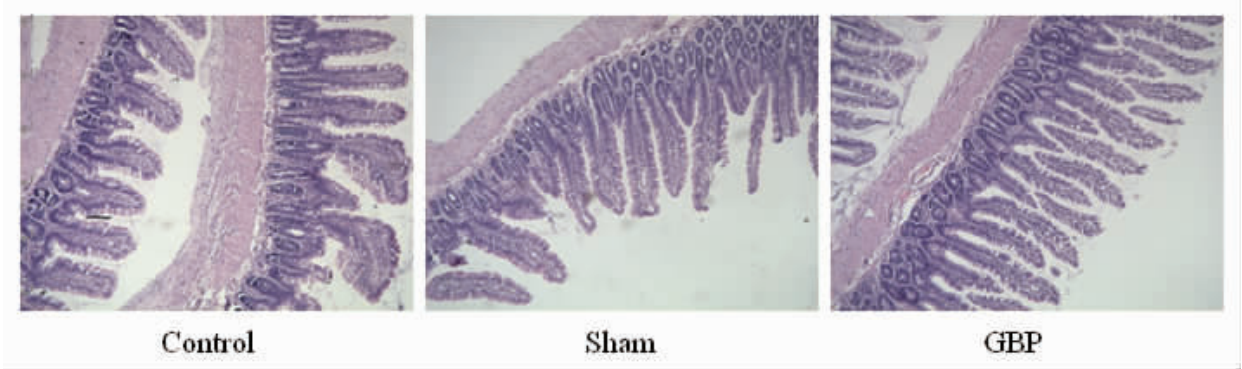


图 1 三组大鼠的肠黏膜病理形态

Fig. 1 Morphology of the intestinal mucosal surface from 3 groups

表 1 各组大鼠肠黏膜形态指标比较($\bar{x} \pm s$)

Table 1 Comparison for the morphological parameters of intestinal mucosa among the groups

Group	Mucosal thickness (μm)	Villus height (μm)
Control group	492 ± 41	339 ± 14
Sham group	500 ± 31	342 ± 15
GBP group	$672 \pm 39^{**}$	$445 \pm 19^{**}$

Note: $^{**} P < 0.01$ compared with sham group

2.2 表皮生长因子的表达

假手术组和对照组肠黏膜中 EGF 的荧光强度无显著差异 ($P > 0.01$) ;胃转流术组大鼠肠黏膜中 EGF 的荧光强度显著强于假手术组($P < 0.01$) ,见图 2。

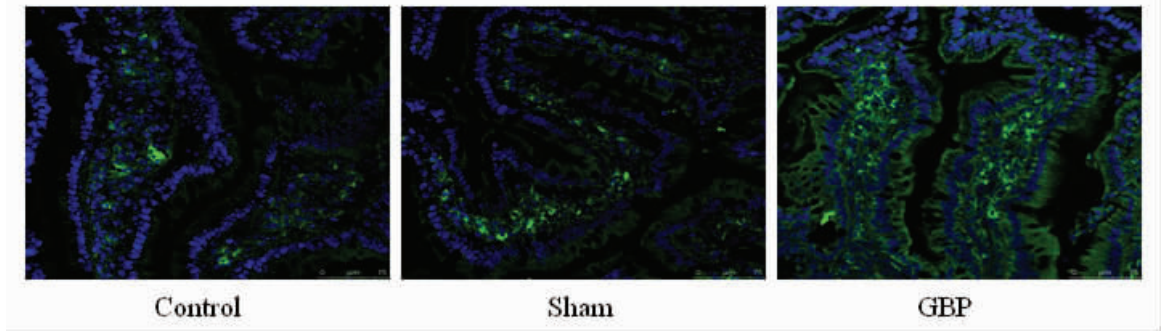


图 2 肠黏膜中 EGF 的表达

Fig. 2 Expression of EGF in the intestinal mucosa

2.3 胰岛素样生长因子-1 的表达

假手术组和对照组肠粘液中 IGF-1 的荧光强度无显著差

异($P>0.01$);胃转流术组大鼠肠粘液中 IGF-1 的荧光强度显著强于假手术组($P<0.01$),见图 3。




图 3 肠粘液中 IGF-1 的表达

Fig. 3 Expression of IGF-1 in the intestinal mucosa

3 讨论

胃转流术最初用于治疗重度肥胖,随后的回顾性分析发现胃转流术能有效地降低血糖水平,能使以胰岛素抵抗为主的 2 型糖尿病患者获得长期且稳定的血糖控制。目前,国内外已逐步将胃转流术用于重度肥胖伴 2 型糖尿病患者的治疗^[1-5]。既往的研究多集中于胃转流术减肥和降糖的分子机制^[6-9],较少有研究关注胃转流术后对吻合口远端肠黏膜形态及功能的影响。本研究发现胃转流术可造成吻合口远端肠管黏膜的显著增生,并发现这种黏膜的增生伴随着 EGF 和 IGF-1 表达水平的显著升高,提示后两者可能参与了黏膜增生的过程。

既往尚无研究发现胃转流术后远端肠管黏膜增生的现象^[12]。短肠综合征是造成残留肠管黏膜增生的经典模型,大部分肠管被切除后造成残余肠管黏膜的代偿性增生^[13-16]。胃转流术造成全段十二指肠和近端空肠被旷置,本研究发现其同样可造成远端肠管黏膜轻度而显著的增生。这种增生的功能意义目前尚不清楚。从机体的代偿意义上来考虑,增生的肠黏膜可能是代偿被旷置肠管功能的一种适应性反应。在行胃转流术的患者中,未出现明显的胃肠道症状,这也有可能是远端肠管黏膜增生和适应性反应的结果。采取抑制这种代偿性肠黏膜增生的措施后再观察胃肠道反应情况有助于明确这一假设。此外,这种肠黏膜的形态学变化是否有其他功能意义,如是否参与到胃肠道激素的调控和脂质代谢的调控均有待进一步探索。同样,这种代偿性增生的机制也不十分清楚。本研究发现肠黏膜的增生与 EGF 和 IGF-1 表达增加相关,这提示这两种生长因子可能参与了肠黏膜的增生。既往的研究资料表明,多肽类生长因子,如 EGF、IGF-1 和转化生长因子(TGF)等均参与了肠上皮生长的调控,并对肠黏膜损伤后的再生修复有促进作用^[17-20]。而 EGF 和 IGF-1 是否直接决定这种黏膜的增生尚待进一步证实。

综上所述,本研究观察到胃转流术吻合口远端肠黏膜显著增生,且伴随着 EGF 和 IGF-1 表达水平的显著升高,这两种生长因子表达的增加可能参与了肠黏膜的增生。但肠黏膜增生的功能意义和确切机制均有待进一步研究。

参考文献(References)

[1] Collins BJ, Miyashita T, Schweitzer M, et al. Why roux-en-Y? A re-

view of experimental data [J]. Arch Surg, 2007, 142(10): 1000-1003

[2] Moore EE. Conversion of jejunioileal bypass to gastric bypass [J]. Arch Surg, 1981, 116(8): 1099

[3] Smoot TM, Xu P, Hilsenrath P, et al. Gastric bypass surgery in the United States, 1998-2002 [J]. Am J Public Health, 2006, 96 (7): 1187-1189

[4] Lee WJ, Chong K, Ser KH, et al. Gastric bypass vs sleeve gastrectomy for type 2 diabetes mellitus: a randomized controlled trial [J]. Arch Surg, 2011, 146(2): 143-148

[5] Czupryniak L, Strzelczyk J, Cypriak K, et al. Gastric bypass surgery in severely obese type 1 diabetic patients [J]. Diabetes Care, 2004, 27 (10): 2561-2562

[6] Cummings DE, Overduin J, Foster-Schubert KE. Gastric bypass for obesity: mechanisms of weight loss and diabetes resolution [J]. J Clin Endocrinol Metab, 2004, 89(6): 2608-2615

[7] Curry TB, Roberts SK, Basu R, et al. Gastric bypass surgery is associated with near-normal insulin suppression of lipolysis in nondiabetic individuals [J]. Am J Physiol Endocrinol Metab, 2011, Epub ahead of print

[8] Beckman LM, Beckman TR, Sibley SD, et al. Changes in gastrointestinal hormones and leptin after roux-en-Y gastric bypass surgery [J]. JPEN J Parenter Enteral Nutr, 2011, 35(2): 169-180

[9] Dirksen C, Hansen DL, Madsbad S, et al. Postprandial diabetic glucose tolerance is normalized by gastric bypass feeding as opposed to gastric feeding and is associated with exaggerated GLP-1 secretion: a case report [J]. Diabetes Care, 2010, 33(2):375-377

[10] 王文生, 肖卫东, 张朝君, 等. 血管紧张素转换酶抑制剂促进短肠综合征大鼠肠黏膜的适应性代偿 [J]. 重庆医学, 2010, 39(10): 1203-1208

Wang WS, Xiao WD, Zhang CJ, et al. Angiotensin converting enzyme inhibitor improves bowel adaptation in a massive intestinal resection rat model [J]. Chongqing Medical Journal, 2010, 39(10): 1203-1208

[11] Westergaard H. Short bowel syndrome [J]. Semin Gastrointest Dis, 2002, 13(4): 210-220

[12] Spak E, Björklund P, Helander HF, et al. Changes in the mucosa of the Roux-limb after gastric bypass surgery [J]. Histopathology, 2010, 57(5): 680-688

(下转第 3484 页)

由此可见 E-cad、EGFR、MMP9 在肺癌的侵袭与转移过程中互相调控,且与 NSCLC 的增殖、浸润、转移密切相关。因此,三者可以作为判断其生物学行为、预测转移趋势的有价值的指标。临床上联合检测这几项因子的表达有助于推测肿瘤的转移能力。对早期肺癌术后病人,联合检测者三项指标,结合常规术前评估检查及术后病理情况,可以更加科学地预测其恶性程度,以及判断是否可能存在微转移灶,以便更好地决定术后治疗方案。

参考文献(References)

- [1] Liotta LA, Stetler-Stevenson WG. Tumor invasion and metastasis: an imbalance of positive and negative regulation [J]. Cancer Res(suppl), 1991,51(19):5054-5059
- [2] Gloushankova NA.Changes in regulation of cell-cell adhesion during tumor transformation[J]. Biochemistry (Mosc) 2008 7:742-750
- [3] Yap AS, Crampton MS, Hardin J. Making and breaking contacts: the cellular biology of cadherin regulation [J]. Curr Opin Cell Biol, 2007 5:508-514
- [4] Jiang S,Massarweh S, Osbor K, et al.Mechanism of tamoxifen resistance:increased estrogen receptor-HER2/neu cross-talk in ER/HER2-positive breast cancer [J].National Cancer Institute,2004,96 (2): 926-935
- [5] 谢一利,楼丽广.表皮生长因子受体信号通路及其靶向肿瘤治疗[J].国外医学 肿瘤学分册 2005 32(5) 361
Xie Yi-li, Lou Li-guang. The epidermal growth factor receptor signal path and targeted cancer treatment [J]. Foreign medical, Oncology sub-volume, 2005,32(5),361
- [6] Rytkenon AK,Vaara M, Nethanel T,et al.Distinctive activities of DNA polymerases during human DNA replication [J] FEBS J,2006:273
- [7] Fernandez-Sanchez M,Gamboa-Dominguez A, Uribe N, et al. Clinical and pathological predictors of the response to neoadjuvant anthracycline chemotherapy in locally advanced breast cancer [J]. Med oncol, 2006:23(2):171-182
- [8] Skrzydlewska E, Sulkowska M, Koda M,et al.Proteolytic-antiproteolytic balance and its regulation in carcinogenesis [J].World J Gastroenterol,2005,11(9):1251-1266
- [9] Cox G,, Jones JL, O.Byrne KJ, et al. Matrix metalloproteinase and epidermal growth factor signal pathway in operable non-small cell lung cancer. Clin Cancer Res, 2000,6(6):2349-2355
- [10] Xie T, Yuan XL, Yu SY,et al.Interference of HIF-1 α by RNA reduces the expression of matrix metalloproteinase-2 in human cervical carcinoma HeLa cells[J]. Ai Zheng 2008 6:600-605
- [11] 刘联,张昕,王秀问,等.E-钙粘素介导的细胞粘附通过 EGFR 激活卵巢癌细胞 P13K-Akt 信号通路 [J]. 现代妇产科进展 2007 4 : 270-273
Liu lian, Zhang xin, Wang Xiu-wen, et al. E - calcium sticky meal mediated cell adhesion activate ovarian cancer cell P13K - Akt signalling pathways through EGFR [J] . Modern obstetrics and progress, 2007 4 270-273
- (上接第 3448 页)
- [13] De Francesco A, Malfi G, Delsedime L, et al. Histological findings regarding jejunal mucosa in short bowel syndrome [J]. Transplant Proc, 1994, 26(3): 1455-1456
- [14] Alpers DH. How adaptable is the intestine in patients with short-bowel syndrome [J]. Am J Clin Nutr, 2002, 75(5): 787-788
- [15] Li N, Zhu W, Guo F, et al. Rehabilitative therapy of short bowel syndrome: experimental study and clinical trial [J]. Zhonghua Wai Ke Za Zhi, 2000, 38(8): 565-569
- [16] Ziegler TR, Fernández-Estívariz C, Gu LH, et al. Distribution of the H⁺/peptide transporter PepT1 in human intestine: up-regulated expression in the colonic mucosa of patients with short-bowel syndrome [J]. Am J Clin Nutr, 2002, 75(5): 922-930
- [17] Basuroy S, Sheth P, Mansbach CM, et al. Acetaldehyde disrupts tight junctions and adherens junctions in human colonic mucosa: protection by EGF and L-glutamine [J]. Am J Physiol Gastrointest Liver Physiol, 2005, 289(2): G367-375
- [18] Hashimoto N, Ohyanagi H. IGF-I stimulates mucosal growth in ileal Thiry-Vella fistulas [J]. Hepatogastroenterology, 2001, 48 (38): 413-415
- [19] Dahly EM, Guo Z, Ney DM. IGF-I augments resection-induced mucosal hyperplasia by altering enterocyte kinetics [J]. Am J Physiol Regul Integr Comp Physiol, 2003, 285(4): R800-808
- [20] Al Haj Ali M, Mensah-Brown E, Chandranath SI, et al. Distribution of insulin like growth factor-1 (IGF-1) and its receptor in the intestines of the one-humped camel (Camelus dromedarius) [J]. Growth Factors, 2003, 21(3-4): 131-137