doi: 10.13241/j.cnki.pmb.2018.06.031

儿童胸腺淋巴上皮瘤样癌的临床病理分析

高 秋[1] 牛会林[1] 胡悦林[2] 古聪敏[1] 施 全[1] 夏健清[1] 曾 亮[1]

(1 广州市妇女儿童医疗中心病理科 广东 广州 510623;2 广州市妇女儿童医疗中心放射科 广东 广州 510623)

摘要 目的:探讨儿童胸腺淋巴上皮瘤样癌(lymphoepithelioma-like carcinoma,LELC)的临床病理学特征、免疫表型、诊断和鉴别诊断。**方法:**分析 2 例 LELC 患儿的临床表现、病理形态和免疫表型,并进行文献复习。**结果:**1 例发生于 6 岁男童,1 例发生于 10 岁女童,以发热、胸痛就诊。大体检查肿物结节状,有包膜,切面实性灰褐色,质软。组织学上肿瘤细胞呈巢状、条索状排列,肿瘤细胞合体样,细胞核大,空泡状,核仁明显,核分裂像易见,间质大量小淋巴细胞浸润。免疫组化标记显示 CK、CK5/6、CK7、CK8/18 阳性,OCT-4、SALL-4、GCP3、AFP 阴性,淋巴造血细胞标记阴性。EB 病毒原位分子杂交检查示 EBV 阳性。**结论:**LELC 是儿童少见的肿瘤,根据临床病理学特征和免疫表型容易诊断,诊断需与生殖细胞肿瘤及淋巴瘤鉴别,患者预后较差。

关键词:淋巴上皮瘤样癌;临床病理学;儿童肿瘤;胸腺

中图分类号:R736.3 **文献标识码:**A **文章编号:** 1673-6273(2018)06-1146-04

Clinicopathological Analysis of Thymic Lymphoepithelioma-like Carcinoma in Children

GAO Qiu[1], NIU Hui-lin[1], HU Yue-lin[2], GU Cong-min[1], SHI Quan[1], XIA Jian-qing[1], ZENG Liang[1]

(1 Department of pathology Guangzhou, Guang Dong, 510623, China;

2 Department of Radiology, Guangzhou Women and Children's Medical Center, Guangzhou, Guangdong, 510623, China)

ABSTRACT Objective: To study the clinicopathological features, immunophenotype and differential diagnosis of thymic lymphoepithelioma-like carcinoma (LELC) in children. **Methods:** Two cases of children with lymphoepithelioma-like carcinoma of thymus were retrieved from our institution. The clinical, radiological and pathological features were analyzed along with a literature review. **Results:** A boy and a girl with LELC were enrolled in this study. Grossly, cut surface of tumor appeared as the gray tissue lump detected. Histologically, the tumors were composed of undifferentiated large cells, either loosely or closely packed, with the nested and trabecular growth pattern. The tumor cells were generally oval or polygonal in shape, while the demarcation between the cells was indistinct and form the syncytial appearance. The nuclei were vesicular and had one or more prominent nucleoli. There were abundant infiltrates of lymphocyte and plasma cells among the tumor nests. The tumor cells showed positive expression of CK, Ki-67. The stromal lymphocytes mainly expressed CD3 and CD8. EBER was positive in the entire tumor cells. The follow up data, which terminated at June 2017, demonstrate 1cases was alive with tumor recurrent and 1 case lived 6 months after operation. **Conclusions:** Lymphoepithelioma-like carcinoma occurred of thymus in children is rare. It has distinctive morphologic features and poor prognosis. The accurate diagnosis is dependent on the combination of histologic and immunohistochemical examination.

Key words: Lymphoepithelioma-like carcinoma; Clinic-pathology; Thymus; Children neoplasm

Chinese Library Classification(CLC): R736.3 Document code: A

Article ID: 1673-6273(2018)06-1146-04

前言

淋巴上皮瘤样癌 (Lymphoepithelioma-like carcinoma, LELC)是一种较为少见的恶性肿瘤类型,发生在唾液腺、食道、胃、胸腺、甲状腺、乳腺、肺、子宫、子宫颈、膀胱和皮肤。有研究显示其与 Epstein Barr 病毒有关[1,2]。发生于胸腺的 LELC 也称淋巴上皮样胸腺癌,是一种罕见的肿瘤,具有高侵袭性、转移性和复发率,通常预后较差[3]。国内外对于儿童胸腺淋巴上皮瘤样癌的总结报道少见。现总结本院收治的 2 例儿童 LELC 患者的临床病理资料、影像学病理检查结果,并复习相关文献总结其诊断、鉴别诊断要点如下。

作者简介:高秋(1974-),硕士,副主任医师,研究方向:儿童肿瘤的病理诊断,电话:18198907826, E-mail: gaoqiu226@163.com

(收稿日期:2017-10-19 接受日期:2017-11-10)

1 资料与方法

1.1 临床资料

收集广州市妇女儿童医疗中心 2015 年 10 月至 2017 年 2 月收治的 2 例胸腺淋巴上皮瘤样癌儿童的临床病理资料,主要包括年龄、性别、临床症状及体征、影像学改变、手术所见、病理诊断及分型等。

1.2 检测方法

肿瘤手术切除组织 4%中性甲醛液固定,组织常规脱水,石蜡包埋制片并 HE 染色,显微镜下观察,由两位病理医师确诊并分型。免疫组织化学染色使用 Leica Bond-Max 全自动免疫组织化学仪,一抗[CK、CK5/6、CK7、CK8/18、CK20、波形蛋白、

Ki-67、甲胎蛋白(AFP)、OCT4、SALL4、CD3、CD5、CD20、Pax5、白细胞共同抗原(LCA)]均购自 Novocastra 公司，显色系统为 Leica 公司产品 Bond 检测系统，一抗工作液为 Bond 产品。以已知阳性组织为阳性对照，PBS 代替一抗为空白对照。

1.3 原位杂交方法

应用原位杂交法检测 EB 病毒编码的小 RNA(EBER)的表达，所用试剂为 EBER DIG oligoprobes ISH kit (PanPath, Amsterdam, Netherlands)。

1.4 免疫组化染色结果判定标准

DAB 显色阳性表达呈棕黄色。阳性结果根据阳性细胞的数量和阳性表达的强度综合判定。以阳性细胞 >10%判断为阳性，无阳性细胞判定为阴性，有肯定的阳性细胞但数量 <10%判为灶性阳性，有肯定的阳性细胞但表达强度较弱者判定为弱阳性。

2 结果

2.1 临床资料

2 例患儿中男女各占 1 例，年龄分别为 6 岁、10 岁，就诊原因其一是运动后出现前胸疼痛，伴有低热，另一是无明显诱因出现发热，39.0℃，伴活动后气促，咳嗽。见表 1。

表 1 2 例胸腺 LELC 患儿的临床资料

Table 1 The clinical data of 2 cases of LELC in children

Case	Gender	Age	Clinical symptom	Tumor size(cm^3)	Follow up time (month)
1	Male	6	Chest pain with low fever after exercise	5.6× 5.1× 6.9	Died 6 months after operation
2	Female	10	Fever and shortness of breath, cough	5× 5× 6	Recurrence was found 5 months after operation

2.2 大体形态

两例大体观察相似，灰红灰褐色碎组织一堆，部分呈结节状，可见包膜，切面灰红灰黄色，胶冻样，质软，见图 1。

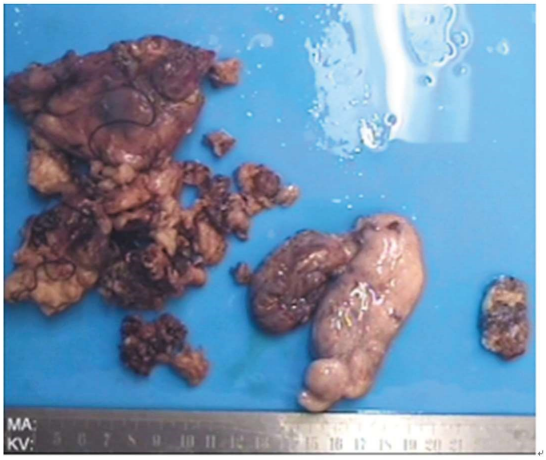

图 1 肿瘤的大体形态

Fig.1 Gross tumor morphology

2.3 组织形态

2 例镜下形态相似。镜下见呈巢状、条索状排列的上皮样瘤细胞，淋巴浆细胞丰富，淋巴滤泡形成(见图 2①，10×)，肿瘤细胞合体样，细胞界限不清，肿瘤细胞核大，空泡状，染色质细小，一个或多个嗜酸性大核仁，核分裂像易见 (见图 2②，40×)，间质纤维组织增生，局灶可见坏死，周围组织细胞浸润，表面可见少许胸腺组织，可伴有钙化(见图 2③，4×)。

2.4 免疫组织化学检测结果

CK(+)，CK5/6(+)，CK8/18(+)，CK7(灶性 +)，见图 3(①-③，20×)；CK20(-)，OCT-4(-)，SALL-4(-)，CD3/CD5(淋巴细胞 +)，Ki-67(30%+)，见图 4(20×)。

2.5 原位杂交结果

2 例均为阳性，见图 5。

2.6 影像学表现

前纵隔见类圆形肿物，平扫肿物密度欠均匀，中央见稍低密度区，肿物实质内未见 / 见钙化密度影，增强扫描肿物不均匀 / 中度强化，中央见低强化区，见图 6。

2.7 术中所见

纵隔内肿物，肿物无明显包膜，边界尚清，位于右前上纵隔，局部与右前胸壁粘连，推挤胸腺，外观呈淡黄色，质地较韧且脆。

2.8 随访

采用电话随访患者家属，2 例均获随访，1 例术后存活 6 个月，1 例术后 5 个月肿瘤复发。

3 讨论

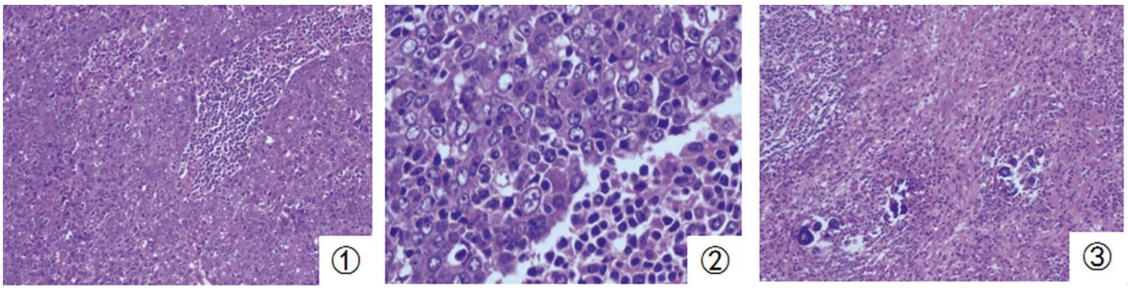

图 2 LELC 的组织学形态

Fig.2 Histological morphology of LELC

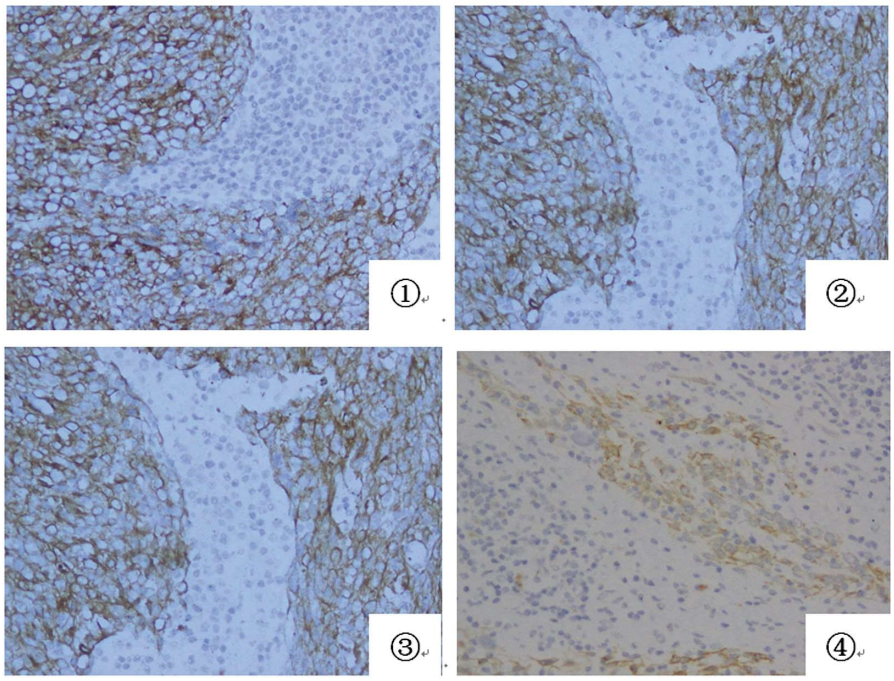

图 3 LELC 的免疫组化结果(CK、CK5/6、CK8/18、CK7 阳性)

Fig.3 Immunohistochemical results of LELC (CK, CK5/6, CK8/18, CK7 positive)

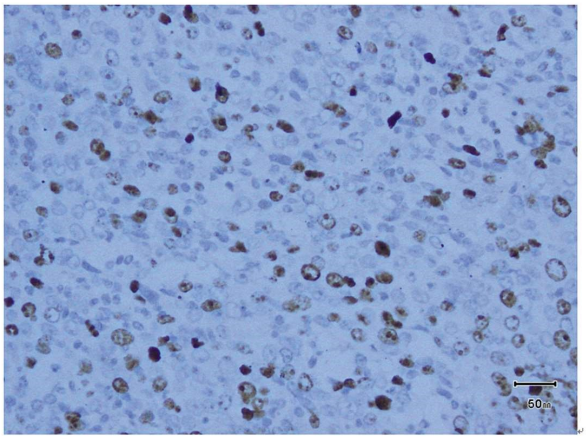

图 4 LELC 的免疫组化结果(Ki-67 30%阳性)

Fig.4 Immunohistochemical results of LELC (Ki-67 30%positive)

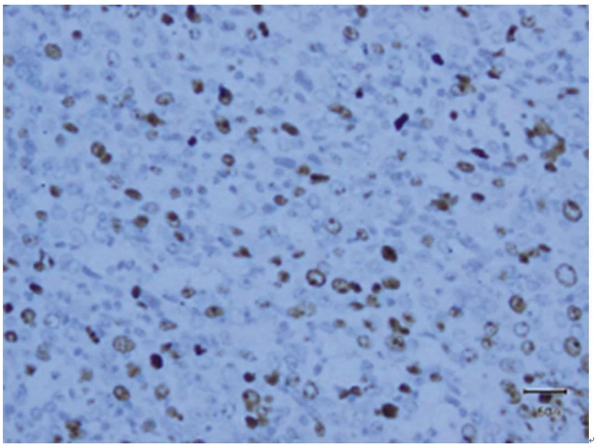

图 5 LELC 的原位杂交结果(EBER 阳性)

Fig.5 In situ hybridization results of LELC(EBER positive)

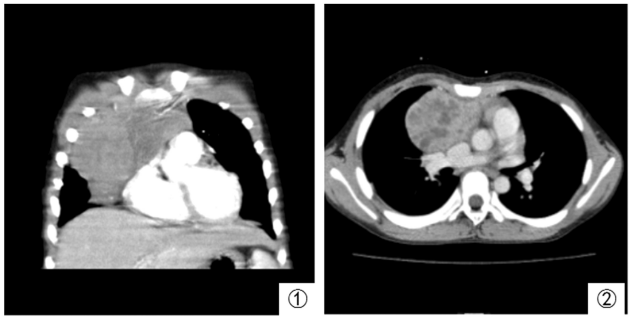

图 6 肿瘤的影像学表现

Fig.6 Imaging findings of the tumor

① CT 增强冠状位 CT enhanced coronal position

② CT 增强横断位 CT enhanced cross section

儿童肿瘤中约 92%的儿童恶性肿瘤为原发性肉瘤和胚胎性肿瘤，属于非上皮性恶性肿瘤，而上皮癌仅占 3-4%。胸腺癌是起源于胸腺上皮的罕见肿瘤[4]，发病率低于 6/10 万人。淋巴上皮瘤样胸腺癌是一种侵袭性高和易于转移的高级别恶性肿瘤，可以伴有副肿瘤综合征，如多发性肌炎[5]。胸腺癌在儿童中更为少见，占所有儿童肿瘤小于 1%。胸腺淋巴上皮瘤样癌是侵袭性胸腺癌的一种组织学亚型，大多与 EB 病毒感染相关，但是在儿童国内外仅报道 14 例[6-17]。

淋巴上皮瘤样癌 LELC 类似于鼻咽和扁桃体的 " 淋巴上皮癌 " 的表现，癌细胞较大，呈多角性或梭形，排列呈巢状或弥散成片，空泡状细胞核，较突出的嗜伊红性核仁，胞质少边界不清，另一特征是还有 " 合体细胞样 " 的表现，无角化和细胞间桥；瘤细胞之间或瘤细胞巢之间不同程度的淋巴细胞浸润，有时可见浆细胞[18]。LELC 具有显著的细胞异型性，免疫表型 CK、CK5/56、CK8/18 阳性，CK7 灶性表达、不表达 CK20、间质淋巴

细胞为外周 T 淋巴细胞，原位杂交显示癌细胞 EBV-DNA 阳性。但儿童胸腺癌极为罕见，WHO 曾定义胸腺癌为 C 型胸腺腺瘤[19]。2004 年，因其比胸腺腺瘤更显著的细胞异型性和较差的临床预后被重新定义为胸腺癌，通过免疫表型可与之鉴别。当淋巴细胞很少时，似低分化鳞癌，儿童鳞状细胞癌发病率极低，组织学癌巢少见淋巴细胞。此外，还须和胸腺淋巴母细胞瘤及生殖细胞来源的肿瘤相鉴别，组织学缺乏上皮细胞巢，免疫组化两种肿瘤分别 TdT 及 OCT、SALL4 阳性可鉴别。有文献报道一例 75 岁碰撞瘤的病例，即皮肤同时发生的 LELC 和边缘区淋巴瘤[20]。本组 2 例儿童胸腺淋巴上皮瘤样癌具有典型的组织学表现，免疫组化 CK 阳性，辅助 EBER 检查阳性，可作出明确病理诊断.对于纵隔来源的生殖细胞源性恶性肿瘤，儿童可见精原细胞瘤、胚胎性癌、卵黄囊瘤等，可通过免疫组化检测 PLAP、AFP 等指标加以鉴别，血清学的一些指标如 HCG、AFP 等可有一些提示，而单凭影像学及临床发热症状，难以鉴别。

目前，LELC 的治疗以手术为主，由于病变部位及肿物浸润性生长，手术尚不能完整切除。对于不能手术的患者，可采用放射治疗和 / 或姑息性化疗，但化疗尚没有最佳治疗方案。有报道 22 岁的晚期难治性淋巴上皮瘤样胸腺癌男性患者进行常规卡铂加紫杉醇治疗，随后卡铂加纳米颗粒白蛋白结合型紫杉醇的治疗，获得部分缓解[21]。发生在胸腺的淋巴上皮瘤样癌生存期短，尚没有最佳的化疗方案[22]。对于其发生、发展机制及术后化疗、放疗的敏感性等方面尚需更多临床病例的积累及探讨研究。比较基因组杂交结果显示在胸腺癌存在染色体的一些改变，但其具体的诊断意义还有待进一步研究[23]。

参 考 文 献(References)

[1] Khokhar N, Nasir H, Amir M, et al. Lymphoepithelioma-Like Carcinoma of the Esophagus: A Rare Tumor [J]. J Coll Physicians Surg Pak, 2017, 27(9): S114-S116

[2] Haga K, Aoyagi T, Kashiwagi A, et al. Lymphoepithelioma-like carcinoma of the renal pelvis[J]. Int J Urol, 2007, 14(9): 851-853

[3] Gomez JMD, Syed G, Co MLF, et al. A rare highly aggressive tumour: lymphoepithelioma-like thymic carcinoma[J]. BMJ Case Rep, 2017

[4] Engels EA, Pfeiffer RM. Malignant thymoma in the United States: demographic patterns in incidence and associations with subsequent malignancies[J]. Int J C ancer, 2003, 105(4): 546-551

[5] Koppula BR, Pipavath S, Lewis DH. Epstein-Barr virus (EBV) associated lymphoepithelioma-like thymic carcinoma associated with paraneoplastic syndrome of polymyositis: a rare tumor with rare association[J]. Clin Nucl Med, 2009, 34(10): 686-688

[6] Wick MR, Scheithauer BW, Dines DE. Thymic neoplasia in two male siblings[J]. Mayo Clin Proc, 1982, 57: 653-656

[7] Marino M, Mü ller Hermelink HK. Thymoma and thymic carcinoma. Relation of thymoma epithelial cells to the cortical and medullary differentiation of thymus [J]. Virchows Arch A Pathol Anat Histopathol, 1985, 407: 119-149

[8] Fujii T, Kawai T, Saito K, et al. EBER.1 expression in thymic carcinoma[J]. Acta Pathol Jpn, 1993, 43: 107-110

[9] Ilhan I, Kutluk T, Gö ğ ü § S, et al. Hypertrophic pulmonary osteoarthropathy in a child with thymic carcinoma: an unusual presentation in childhood[J]. Med Pediatr Oncol, 1994, 23: 140-143

[10] Niehues T, Harms D, Jürgens H, et al. Treatment of pediatric malignant thymoma: long term remission in a 14 year old boy with EBV associated thymic carcinoma by aggressive, combined modality treatment[J]. Med Pediatr Oncol ,1996, 26: 419-424

[11] Stéphan JL, Galambrun C, Boucheron S, et al. Epstein-Barr virus-positive undifferentiated thymic carcinoma in a 12 year old white girl[J]. J Pediatr Hematol Oncol , 2000, 22: 162-166

[12] Di Cataldo A, Villari L, Milone P, et al. Thymic carcinoma, systemic lupus erythematosus, and hypertrophic pulmonary osteoarthropathy in an 11 year old boy: a novel association [J]. Pediatr Hematol Oncol , 2000, 17: 701-706

[13] Yaris N, Nas Y, Cobanoglu U, et al. Thymic carcinoma in children[J]. Pediatr Blood Cancer, 2006, 47: 224-227

[14] Hsueh C, Kuo TT, Tsang NM, et al. Thymic lymphoepitheliomalike carcinoma in children: clinicopathologic features and molecular analysis[J]. J Pediatr Hematol Oncol, 2006, 28: 785-790

[15] Tacyildiz N, Ugur H, Yavuz G, et al. The coexistence of thymic carcinoma and multiple granulomas in a Turkish child [J]. Pediatr Hematol Oncol , 2007, 24: 301-307

[16] Kili ś -Pstrusińska K, Medyńska A, Zwolińska D, et al. Lymphoepithelioma like thymic carcinomain a 16-year-old boy with nephrotic syndrome-a case report [J]. Pediatr Nephrol, 2008, 23: 1001-1003

[17] Kuniko S,Y usuke O, Hiroshi K, et al. Clinical outcome of thymic lymphoepithelioma like carcinoma: Case report of a 14-year-old male [J]. Oncology Letters, 2014, 8: 2183-2186

[18] Travis WD, Brambilla E, Muller-Hermelink HK, et al. Tumours. Pathology and genetics of tumours of the lung,Pleura, Thymus and Heart[J]. IARC Press, Lyon, 2004: 145-247

[19] Rosai J. Histological typing of tumours of the thymus. In: World Health Organizatoin International histological classification of tumours[J]. Berlin, Springer-Verlag, 1999: 5-15

[20] Gebauer N, Merz H, Ottmann KW, et al. Lymphoepithelioma-like carcinoma and simultaneous marginal zone lymphoma of the skin: a case report[J]. Am J Dermatopathol, 2014, 36(2): e26-29

[21] Shima H, Ozasa H, Tsuji T, et al. Response to chemotherapy with carboplatin plus albumin-bound paclitaxel in a patient with lymphoepithelioma-like thymic carcinoma: A case report[J]. Mol Clin Oncol, 2016, 4(5): 715-718

[22] Mlika M, Boudaya S, Braham E, et al. About thymic carcinomas: challenges in diagnosis and management[J]. Asian Cardiovasc Thorac Ann, 2016, 24(4): 350-354

[23] Veits L, Mechtersheimer G, Steger C, et al. Chromosomal imbalances in carcinoma showing thymus-like elements (CASTLE)[J]. Virchows Arch, 2011, 459(2): 221-226