doi: 10.13241/j.cnki.pmb.2018.23.020

IL-6/STAT3 信号途径介导肉芽肿性乳腺炎的作用研究 *

刁 岩[1] 单昌友[1] 赵 阳[1] 靳耀锋[2] 张淑群[1] 管海涛[1] 王子明[3]

（1 西安交通大学第二附属医院肿瘤科 陕西 西安 710004；2 西安交通大学第二附属医院病理科 陕西 西安 710004；
3 西安交通大学第二附属医院泌尿外科 陕西 西安 710004）

摘要 目的：探讨 IL-6/STAT3 信号途径介导肉芽肿性乳腺炎的机制研究及临床意义。**方法：**收集我院 2017 年 1 月至 2017 年 6 月收治入住的 30 例肉芽肿性乳腺炎患者及 30 例普通患者的血清样本，对肉芽肿性乳腺炎患者同时采集炎性肿块组织样本及距离炎性肿块边缘大于等于 3 cm 且镜检为正常乳腺组织的样本。采用 ELISA 法检测血清样本中的 IL-6 的表达水平，同时采用 Western blot 检测组织样本中 IL-6 和 pSTAT3 蛋白的表达水平并分析二者的相关性。**结果：**与普通患者血清样本相比，肉芽肿性乳腺炎患者血清中 IL-6 的表达水平明显增高(P<0.05)，肉芽肿性乳腺炎组织样本中 IL-6 和 pSTAT3 蛋白的表达水平明显高于毗邻的正常乳腺组织(P<0.01)，IL-6 表达与组织 STAT3 磷酸化水平具有明显的正相关性(r=0.353，P<0.05)。**结论：**IL-6/STAT3 信号途径可能介导肉芽肿性乳腺炎的发生发展。

关键词：肉芽肿性乳腺炎；组织；血清；白介素 -6；信号转导与转录活化因子 3；相关性

中图分类号：R655.8 **文献标识码：**A **文章编号：**1673-6273(2018)23-4486-03

Role of IL-6/STAT3 Signaling Pathway in the Granulomatous Mastitis*

DIAO Yan[1], SHAN Chang-you[1], ZHAO Yang[1], JIN Yao-feng[2], ZHANG Shu-qun[1], GUAN Hai-tao[1], WANG Zi-ming[3]

(1 Department of Oncology, the Second Affliated Hospital of Xi'an Jiaotong University, Xi'an, Shaanxi, 710004, China;
2 Department of Pathology, the Second Affliated Hospital of Xi'an Jiaotong University, Xi'an, Shaanxi, 710004, China;
3 Department of Urology, the Second Affliated Hospital of Xi'an Jiaotong University, Xi'an, Shaanxi, 710004, China)

ABSTRACT Objective: To investigate the role of IL-6/STAT3 signaling pathway in the granulomatous mastitis. **Methods:** Serum samples from 30 cases of patients with GLM and 30 cases of normal patients who admitted in our hospital from January 2017 to December 2017 were collected. Inflammatory mass samples were collected from patients with GLM. the expression levels of IL-6 and pSTAT3 protein in tissue samples was detected by Western blot and the correlation of IL-6 and pSTAT3 protein expression was analyzed. **Results:** The expression of IL-6 in serum of GLM patients was significantly higher than that of normal control patients (P<0.05); The expression levels of IL-6 and pSTAT3 protein in granulomatous mastitis tissue samples were significantly higher than those in adjacent normal breast tissues(P<0.01). There was a significant positive correlation of IL-6 expression with the phosphorylation STAT3(r=0.353, P<0.05). **Conclusion:** IL-6/STAT3 signaling pathway may mediate the occurrence and development of granulomatous mastitis.

Key words: Granulomatous lobular mastitis; Tissue; serum; IL-6; STAT3; Correlation

Chinese Library Classification(CLC): R655.8 Document code: A

Article ID: 1673-6273(2018)23-4486-03

前言

肉芽肿性乳腺炎以乳腺小叶为中心，故称为肉芽肿性小叶性乳腺炎(Granulomatous lobular mastitis，GLM)，是非哺乳期乳腺炎的重要表现形式[1,2]。随着生活水平的提升及卫生护理条件的改善，哺乳期乳腺炎等急性炎症的发生率显著降低[3]，而非哺乳期乳腺炎如浆细胞性乳腺炎和肉芽肿性乳腺炎的发生率逐年攀升，其阳性表达率占乳腺良性病变的 1.8%[3,4]，严重影响了患者的生活质量。肉芽肿性乳腺炎在临床上主要表现为不规则的单或双侧乳腺肿块伴疼痛，早期无明显的皮肤红肿[5,6]，易与乳腺癌诊断混淆[7,8]，中期多表现为局部皮肤红肿，但不涉及乳头和乳晕区，并且给予抗生素治疗后症状缓解不明显，晚期患者病情进展较快，炎症进一步发展，可形成脓肿、溃疡及窦道并且迁延不愈，但无论处于哪一期均不伴有严重的全身性症状[9]，其发生机制尚不十分清楚。

白细胞介素 -6(interleukin-6，IL-6)是目前被认为与炎症反应密切相关的炎症细胞因子[10,11]，其介导的信号转导与转录活化因子 3 (signal transducer and activator of transcription 3, STAT3)是近年来发现的一个由细胞因子刺激并激活的信号通路分子，在细胞的增殖、分化、凋亡以及免疫反应调节等许多重要的生物学过程中扮演着重要的角色。有研究报道[12,13]磷酸化的 STAT3 能够进一步促进 IL-1β、IL-10 及 TNF-α 的表达进一步加剧炎症反应。亦有报道显示[14]IL-6/STAT3 信号通路与非哺乳期乳腺炎之浆细胞性乳腺炎密切相关，但 IL-6/STAT3 信号

* 基金项目：陕西省重点研发计划项目(2017SF-250)

作者简介：刁岩(1978-)，硕士，主治医师，研究方向：乳腺疾病

(收稿日期：2018-03-07 接受日期：2018-05-05)

通路是否参与肉芽肿性乳腺炎的发生目前尚无文献报道。本研究主要探讨了肉芽肿性乳腺炎患者血清样中 IL-6 及组织中磷酸化 STAT3 的表达，分析二者在肉芽肿性乳腺炎中的相关性，以期为临床诊疗提供新的思路和实验依据。

1 资料与方法

1.1 临床资料及纳入标准

收集我院 2017 年 1 月至 2017 年 12 月收治入住的 25 例肉芽肿性乳腺炎患者，主要为经产妇，产后 1.5~6 年内多发，年龄 23~36 岁，平均年龄(26.15± 5.21)岁，患者的病程分布为 1 个月 ~12 个月；其中双侧乳腺肉芽肿性乳腺炎炎性肿块 1 例(4%)，左侧乳腺肉芽肿性乳腺炎炎性肿块 9 例(36%)，右侧乳腺肉芽肿性乳腺炎炎性肿块 15 例(60%)。研究对象的入选标准：① 患者均经皮组织病理活检确诊为肉芽肿性乳腺炎；② 不同程度的存在乳房肿块，细菌培养结果提示阴性；③ 知情同意。排除标准：① 有恶性肿瘤者；② 有自身免疫性疾病者；③ 肝肾功能障碍或伴有其他系统疾病；④ 血液疾病[6,8,15]。

1.2 研究方法

1.2.1 实验样本获取 采取 25 例肉芽肿性乳腺炎患者及 30 例普通患者的血清样本，对肉芽肿性乳腺炎患者同时经皮获取炎性肿块组织样本及距离炎性肿块边缘大于等于 3 cm 且镜检为正常乳腺组织的样本。

1.2.2 酶联免疫反应 血清样本 IL-6 浓度测定采用酶联免疫反应(Enzyme-linked immunosorbent assay，ELISA)试剂盒(CircuLex Human IL-6 ELISA Kit; CycLex Co., Ltd. Japan) 进行测定。所有步骤严格按照试剂盒说明书进行操作。

1.2.3 Western blot 组织样本中 IL-6 和 STAT3 分子蛋白的表达水平主要采用 Western blot 试剂盒进行检测分析，相关操作步骤严格按照试剂盒说明执行。

1.3 研究指标

两组血清中 IL-6 的表达差异；肉芽肿性乳腺炎组中正常组织与炎性组织中 IL-6 和 STAT3 分子 mRNA 的表达及二者之间的相关性。

1.4 统计学方法

使用 SPSS16.0 统计分析软件对数据进行分析，计量数据采用($\bar{x}$± s)表示，两组间比较采用两独立样本的 t 检验，相关性分析采用 Pearson 法进行处理，以 P<0.05 表示为差异有统计学意义。

2 结果

2.1 两组血清 IL-6 表达水平的比较

观察组血清 IL-6 的平均浓度(93.45± 6.92)明显高于对照组(62.18± 3.79)，差异具有统计学意义(见表 1，P<0.05)。

表 1 两组血清 IL-6 的表达水平比较

Table 1 Comparison of the expression of serum IL-6 between two groups

Groups	Number of cases	IL-6 (pg/mL)
Observation group	25	93.45± 6.92
Control group	30	62.18± 3.79
P		<0.001

2.2 肉芽肿性乳腺炎炎性组织与正常组织中 IL-6 和 pSTAT3 mRNA 的表达水平

肉芽肿性乳腺炎炎性组织中 IL-6 与 pSTAT3 的蛋白表达水平明显高于肉芽肿性乳腺炎正常组织，差异具有统计学意义(见图 1，P<0.01)。

2.3 肉芽肿性乳腺炎炎性组织与正常组织样本中 IL-6 和 pSTAT3 蛋白表达的相关性分析

经 Pearson 法进行相关性分析，结果显示 IL-6 的表达水平与 STAT3 磷酸化水平具有显著正相关关系(r = 0.353，P<0.05)。

3 讨论

肉芽肿性乳腺炎好发于经产妇女，是一种发生于乳腺器官上的不常见的临床炎性病变[16-18]。临床上虽然该病的发病率不高，但存在症状不典型、易误诊、反复发作及病程难以控制的现象[9,19,20]。然而，到目前为止肉芽肿性乳腺炎的发病机制尚不十分清楚，并且学者们对肉芽肿性乳腺炎的认识存在分歧，因此对于该疾病的探究及发病机理的讨论显得尤为重要。

既往研究表明[21,22]，肉芽肿性乳腺炎作为非哺乳期乳腺炎症，可能与患者食用避孕药或者乳腺创伤后并发的症状。亦有研究表明[23-25]，血清高泌乳素水平与肉芽肿性乳腺炎的发生率

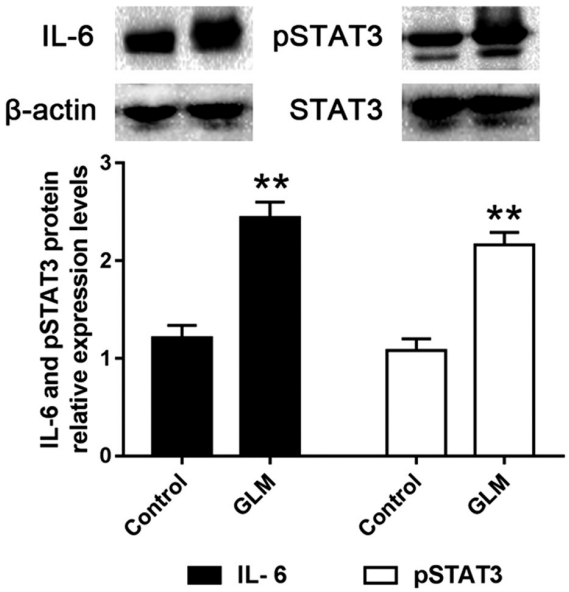

图 1 肉芽肿性乳腺炎性组织与正常组织样本中 IL-6(A)和 pSTAT3(B)蛋白的表达水平。**P<0. 01，肉芽肿性乳腺炎组 vs 正常对照组。

Fig.1 The protein expression levels of IL-6 (A) and pSTAT3 (B) in GLM inflammatory and control group sample tissues. **P<0.01, GLM group vs control group

表 2 肉芽肿性乳腺炎组织样本中 IL-6 与 pSTAT3 蛋白表达的相关性

Table 2 Correlation between IL-6 and p-STAT3 protein in GLM

IL-6	pSTAT3		r	P
	+	-		
+	15	1	0.353	< 0.05
-	2	7		

呈现正相关性,提示肉芽肿性乳腺炎的发生与非哺乳期血清泌乳素水平有关，可能由于内分泌系统紊乱继发的免疫系统疾病。也有一些研究报道[26]在哺乳期患者也会发生肉芽肿性乳腺炎,其机制可能与乳汁分泌不畅堵塞分泌导管产生某种化学反应或者乳汁本身诱发组织产生某种化学物质进而产生一些物质诱导自身免疫性炎症反应。新近研究表明[27-30],对病理活检确诊为肉芽肿性乳腺炎患者的组织进行细菌培养,发现棒状杆菌的合并出现,提示肉芽肿性乳腺炎形成机制与革兰阳性菌的存在有关。尽管有许多种假说的存在,但这些均不能很好解释肉芽肿性乳腺炎的发生与发展。本实验结合前人研究成果,针对肉芽肿性乳腺炎这一炎症属性,检测血清中 IL-6 的表达水平,炎症性肿块中 IL-6 与 pSTAT3 蛋白的表达水平，分析 IL-6 与 pSTAT3 之间表达的相关性,为进一步探究肉芽肿性乳腺炎的发病机制及临床诊疗提供可靠的实验依据。

已有研究报道称 [10,13],IL-6/STAT3 信号通路在炎症反应的过程中扮演着重要的角色。参与了神经病理性疼痛的发生,肿瘤细胞的浸润、转移,干细胞的增殖、转化等过程。近年来,有关报道显示[14],IL-6/STAT3 信号通路与非哺乳期乳腺炎之浆细胞性乳腺炎密切相关,而本研究实验结果显示,肉芽肿性乳腺炎患者血清中 IL-6 的表达水平明显高于正常对照组，提示 IL-6 可能在非哺乳期乳腺炎患者中均有所提升,而肉芽肿性乳腺炎患者炎性肿块中 IL-6 与 pSTAT3 蛋白的表达水平均明显提升,与相应患者的正常组织相比具有显著性差异。紧接着我们进一步分析了 IL-6 与 pSTAT3 表达水平的的相关性，结果提示 IL-6 与 pSTAT3 蛋白的表达呈正相关，进一步说明了 IL-6/STAT3 信号通路与肉芽肿性乳腺炎的发生发展存在密切联系。

综上所述,本实验结果提示肉芽肿性乳腺炎患者血清中的 IL-6 的表达水平及炎性肿块组织中 IL-6 与 STAT3 的磷酸化水平均增高,血清 IL-6 与组织 STAT3 磷酸化水平具有显著正相关关系,IL-6/STAT3 信号通路介导肉芽肿性乳腺炎的发生发展,有望为临床诊疗提供新的方向。

参 考 文 献(References)

[1] Zhou F, Yu LX, Ma ZB, et al. Granulomatous lobular mastitis [J]. Chronic diseases and translational medicine, 2016, 2(1): 17-21

[2] Mahlab-Guri K, Asher I, Allweis T, et al. Granulomatous lobular mastitis [J]. The Israel Medical Association journal: IMAJ, 2015, 17(8): 476-480

[3] Korkut E, Akcay MN, Karadeniz E, et al. Granulomatous mastitis: A ten-year experience at a university hospital [J]. The Eurasian journal of medicine, 2015, 47(3): 165-173

[4] Wang YS, Li QW, Zhou L, et al. Granulomatous lobular mastitis associated with mycobacterium abscessus in south china: A case report and review of the literature [J]. Case reports in infectious diseases, 2017, 2017: 7052908

[5] Zhang L, Hu J, Guys N, et al. Diffusion-weighted imaging in relation to morphology on dynamic contrast enhancement mri: The diagnostic value of characterizing non-puerperal mastitis[J]. European radiology, 2018, 28(3): 992-999

[6] D'Alfonso TM, Ginter PS, Shin SJ. A review of inflammatory processes of the breast with a focus on diagnosis in core biopsy samples [J]. Journal of pathology and translational medicine, 2015, 49(4): 279-287

[7] Wang Z, Wang N, Liu X, et al. Broadleaf mahonia attenuates granulomatous lobular mastitisassociated inflammation by inhibiting ccl5 expression in macrophages [J]. International journal of molecular medicine, 2018, 41(1): 340-352

[8] Li J. Diagnosis and treatment of 75 patients with idiopathic lobular granulomatous mastitis [J]. Journal of investigative surgery: the official journal of the Academy of Surgical Research, 2018: 1-7[Epub ahead of print]

[9] Cheng J, Du YT, Ding HY. granulomatous lobular mastitis: Clinical pathological diagnosis and differential diagnosis [J]. Chinese journal of pathology, 2016, 45(8): 507-512

[10] Akanda MR, Nam HH, Tian W, et al. Regulation of jak2/stat3 and nf-kappab signal transduction pathways; veronica polita alleviates dextran sulfate sodium-induced murine colitis [J]. Biomedicine & pharmacotherapy, 2018, 100: 296-303

[11] Zhu XM, Shi YZ, Cheng M, et al. Serum il-6, il-23 profile and treg/th17 peripheral cell populations in pediatric patients with inflammatory bowel disease[J]. Die Pharmazie, 2017, 72(5): 283-287

[12] Sun M, Huang Y, Li F, et al. Microrna-874 inhibits tnf-alpha-induced remodeling in human fetal airway smooth muscle cells by targeting stat3 [J]. Respiratory physiology & neurobiology, 2018 [Epub ahead of print]

[13] Gao H, Liu L, Zhao Y, et al. Human il-6, il-17, il-1beta, and tnf-alpha differently regulate the expression of pro-inflammatory related genes, tissue factor, and swine leukocyte antigen class in porcine aortic endothelial cells [J]. Xenotransplantation, 2017, 24 (2)[Epub ahead of print]

[14] Liu Y, Zhang J, Zhou YH, et al. Il-6/stat3 signaling pathway is activated in plasma cell mastitis [J]. International journal of clinical and experimental pathology, 2015, 8(10): 12541-12548

[15] Raman RT, Manimaran D. Idiopath=ic granulomatous lobular mastitis masquerading as a breast tumor: A case report [J]. Iranian Red Crescent medical journal, 2016, 18(5): e33982

[16] Omranipour R, Mohammadi SF, Samimi P. Idiopathic granulomatous lobular mastitis - report of 43 cases from iran; introducing a preliminary clinical practice guideline[J]. Breast care, 2013, 8(6): 439-443

(下转第 4438 页)

scarring in a paediatric patient[J]. Ann R Coll Surg Engl, 2017, 99(8): e233-e335

[18] Pozzi M, Zoccali G, Drago MC, et al. Radiotherapy following surgery in keloid treatment: our protocol [J]. G Ital Dermatol Venereol, 2016, 151(5): 492-498

[19] Hsu CK, Lin HH, Harn HI, et al. Caveolin-1 Controls Hyperresponsiveness to Mechanical Stimuli and Fibrogenesis-Associated RUNX2 Activation in Keloid Fibroblasts [J]. J Invest Dermatol, 2018, 138(1): 208-218

[20] Li J, Fu R, Li L, et al. Co-delivery of dexamethasone and green tea polyphenols using electrospun ultrafine fibers for effective treatment of keloid[J]. Pharm Res, 2014, 31(7): 1632-1643

[21] Bijlard E, Steltenpool S, Niessen FB. Intralesional 5-fluorouracil in keloid treatment: a systematic review [J]. Acta Derm Venereol, 2015, 95(7): 778-782

[22] Haubner F, Leyh M, Ohmann E, et al. Effects of botulinum toxin A on patient-specific keloid fibroblasts in vitro[J]. Laryngoscope, 2014, 124(6): 1344-1351

[23] Robinson AJ, Khadim MF, Khan K. Keloid scars and treatment with Botulinum Toxin Type A: the Belfast experience [J]. J Plast Reconstr Aesthet Surg, 2013, 66(3): 439-440

[24] Xiaoxue W, Xi C, Zhibo X. Effects of botulinum toxin type A on expression of genes in keloid fibroblasts[J]. Aesthet Surg J, 2014, 34(1): 154-159

[25] Wilson AM. Eradication of keloids: Surgical excision followed by a single injection of intralesional 5-fluorouracil and botulinum toxin[J]. Can J Plast Surg, 2013, 21(2): 87-91

[26] Van Leeuwen MC, Van der Wal MB, Bulstra AE, et al. Intralesional cryotherapy for treatment of keloid scars: a prospective study[J]. Plast Reconstr Surg, 2015, 135(2): 580-589

[27] 刘爱英,訾绍霞,靳汪洋,等.A 型肉毒毒素在几种皮肤病的应用进展[J].国际皮肤性病学杂志, 2016, 42(3): 184-187
Liu Ai-ying, Zi Shao-xia, Jin Wang-yang, et al. Progress in the application of botulinum toxin type A in several skin diseases [J]. International Journal of Dermatology and Venereology, 2016, 42(3): 184-187

[28] Zhu HY, Bai WD, Li J, et al. Peroxisome proliferator-activated receptor-γ agonist troglitazone suppresses transforming growth factor-β1 signalling through miR-92b upregulation-inhibited Axl expression in human keloid fibroblasts in vitro [J]. Am J Transl Res, 2016, 8(8): 3460-3470

[29] 刘文阁,于波,孙瑛,等.新型药物组合注射治疗瘢痕疙瘩的临床应用初探[J].中华医学美学美容杂志, 2013, 19(6): 460-461
Liu Wen-ge, Yu Bo, Sun Ying, et al. A preliminary study on the clinical application of combined injection of new drugs in the treatment of keloid [J]. Chinese Journal of Medical Aesthetics and Cosmetology, 2013, 19(6): 460-461

[30] 王小玉,王小琴,刘琰,等.面部小面积瘢痕手术切口早期应用 A 型肉毒毒素注射联合强脉冲光照射的临床效果[J].实用皮肤病学杂志, 2013, 6(5): 271-273
Wang Xiao-yu, Wang Xiao-qin, Liu Yan, et al. Effect of incision early combined botulinum toxin type A injections and intense pulsed light treatment for facial small area scar surgery [J]. Journal of Practical Dermatology, 2013, 6(5): 271-273

(上接第 4488 页)

[17] Oltean HN, Soliman AS, Omar OS, et al. Risk factors for chronic mastitis in morocco and egypt [J]. International journal of inflammation, 2013, 2013(184921)

[18] Hur SM, Cho DH, Lee SK, et al. Experience of treatment of patients with granulomatous lobular mastitis [J]. Journal of the Korean Surgical Society, 2013, 85(1): 1-6

[19] Kamyab A. Granulomatous lobular mastitis secondary to mycobacterium fortuitum [J]. World journal of clinical cases, 2016, 4(12): 409-412

[20] Gurleyik G, Aktekin A, Aker F, et al. Medical and surgical treatment of idiopathic granulomatous lobular mastitis: A benign inflammatory disease mimicking invasive carcinoma [J]. Journal of breast cancer, 2012, 15(1): 119-123

[21] Scheinfeld N. Diseases associated with hidranitis suppurativa: Part 2 of a series on hidradenitis [J]. Dermatology online journal, 2013, 19(6): 18558

[22] Al Nazer MA. Idiopathic granulomatus lobular mastitis. A forgotten clinical diagnosis[J]. Saudi medical journal, 2003, 24(12): 1377-1380

[23] Lehman TD, Damania Z, Tschetter CN, et al. Firm, non-tender mass in right breast. Worsening, nonproductive cough. Pleuritic pain. Dx? [J]. The Journal of family practice, 2017, 66(1): 38-41

[24] Holla S, Amberkar MB, Kamath A, et al. Risperidone induced granulomatous mastitis secondary to hyperprolactinemia in a non-pregnant woman-a rare case report in a bipolar disorder [J]. Journal of clinical and diagnostic research: JCDR, 2017, 11(1): FD01-FD03

[25] Yip CH, Jayaram G, Swain M. The value of cytology in granulomatous mastitis: A report of 16 cases from malaysia [J]. The Australian and New Zealand journal of surgery, 2000, 70(2): 103-105

[26] Tolosa T, Verbeke J, Piepers S, et al. Milk production, quality, and consumption in jimma (ethiopia): Facts and producers', retailers', and consumers' perspectives[J]. Preventive veterinary medicine, 2016, 124(9-14)

[27] Mohammadsadegh M. Impact of intramammary tilmicosin infusion as a dry cow therapy[J]. Journal of veterinary pharmacology and therapeutics, 2018, 41(1): 22-27

[28] Vakkamaki J, Taponen S, Heikkila AM, et al. Bacteriological etiology and treatment of mastitis in finnish dairy herds [J]. Acta veterinaria Scandinavica, 2017, 59(1): 33

[29] Taponen S, Liski E, Heikkila AM, et al. Factors associated with intramammary infection in dairy cows caused by coagulase-negative staphylococci, staphylococcus aureus, streptococcus uberis, streptococcus dysgalactiae, corynebacterium bovis, or escherichia coli [J]. Journal of dairy science, 2017, 100(1): 493-503

[30] Johnstone KJ, Robson J, Cherian SG, et al. Cystic neutrophilic granulomatous mastitis associated with corynebacterium including corynebacterium kroppenstedtii [J]. Pathology, 2017, 49(4): 405-412